

# Benign Fibrous Histiocytoma of the Neurocranium

Chrisovalantis A. Tsimiklis\*, Tom Morris

Neurosurgical Department, Royal Adelaide Hospital (RAH), North Terrace, Adelaide, Australian  
Email: \*ctsimiklis29@gmail.com, dr.tommorris@gmail.com

Received October 8<sup>th</sup>, 2013; revised November 5<sup>th</sup>, 2013; accepted December 3<sup>rd</sup>, 2013

Copyright © 2013 Chrisovalantis A. Tsimiklis, Tom Morris. This is an open access article distributed under the Creative Commons Attribution License, which permits unrestricted use, distribution, and reproduction in any medium, provided the original work is properly cited.

## ABSTRACT

Presented is a case of benign fibrous histiocytoma (BFH) involving the calvarium of a 25 years old lady who noticed a depression in her occiput associated with localised pain. Imaging revealed a tumour eroding through the inner and outer skull tables, closely associated with major underlying dural sinuses. She underwent complete macroscopic resection of the tumour and reconstruction of a titanium mesh cranioplasty. Histology favoured a benign process with a diagnosis of BFH of the calvarium given. At 1 year follow-up, the patient is asymptomatic and has not developed recurrence of the tumour.

**Keywords:** Benign Fibrous Histiocytoma; Skull Tumour; Neurocranium

## 1. Introduction

BFH is most often encountered as a soft-tissue neoplasm involving the skin, and although less common, BFH involving other sites including the bony skeleton is seen. Involvement of the skull is particularly rare with only one other case of BFH involving the neurocranium reported in the literature [1]. Here we report a case of a symptomatic BFH involving the occipital bone and discuss the role for minimising the degree of resection in these benign cases.

## 2. Case Report

*Presentation and examination.* A bump was first noted by this 25 years old lady on her occiput 18 months prior to presentation. It was steadily increasing over this period and she had associated pain at the site but was otherwise neurologically intact. There were no overlying changes to the scalp tissue itself. A CT head revealed an expansile lytic process to the right of the midline involving the occipital bone, measuring 40 × 45 mm, and resulting in loss of both the inner and outer tables of the skull (**Figures 1(a) and (b)**). A bone scan showed a solitary photopaenic occipital bone lesion with a peripheral rim of osteoblastic activity (**Figure 2**). On MRI there was a lytic process following CSF signal with peripheral enhance-

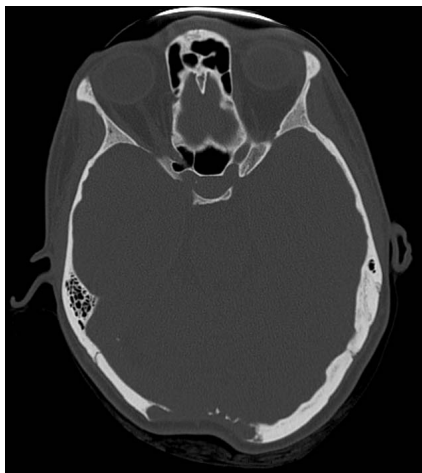ment (**Figures 3(a) and (b)**). There was no invasion into brain parenchyma but it was closely associated with major underlying dural sinuses. The main differential diagnosis was of an eosinophilic granuloma.

*Operation and Postoperative Course.* The patient underwent craniotomy and resection of the tumour. The macroscopic finding intra-operatively was of a pale rubbery mass eroding through the entire thickness of the occipital bone. Frozen section did not provide a clear diagnosis but there were no necrotic features or obvious mitoses. The bone edges were drilled back to normal appearing skull. The mass was carefully dissected off the underlying torcula and dura. Gross total resection was achieved. Titanium mesh was fashioned to cover the bony defect followed by primary wound closure (**Figure 4**). Her post-operative course was uneventful.

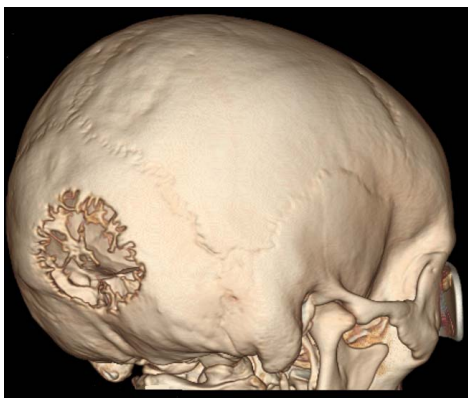
On histological examination, the tissue revealed spindle cell proliferation, with fibromyxoid appearance (**Figure 5**). Some of the spindle cells showed a level of nuclear hyperchromasia, but mitoses were not readily identified, and there was no evidence of necrosis. Immunohistochemistry revealed positive immunostaining for SMA, but negativity for S100, CD34, AE1/3, GFAP, EMA and desmin. An expert opinion was sought and it was felt that the most likely diagnosis was that of benign fibrous histiocytoma of the calvarium.

No further adjuvant treatment was necessary. An MRI

\*Corresponding author.

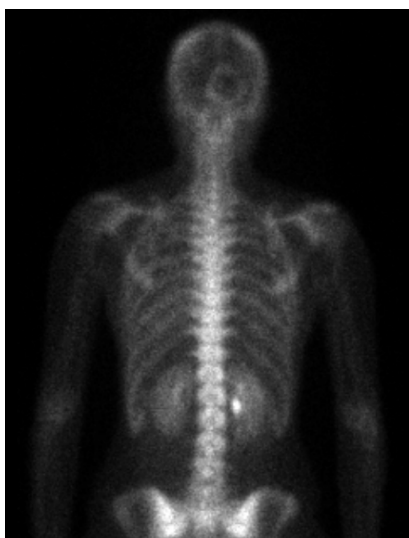


(a)

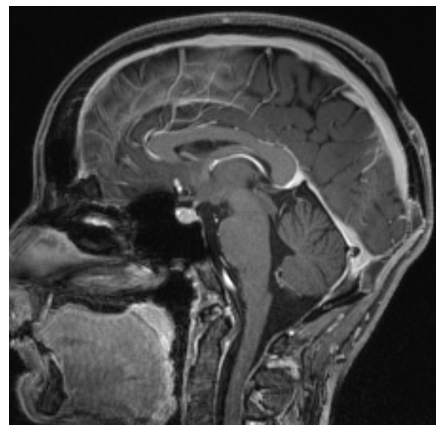


(b)

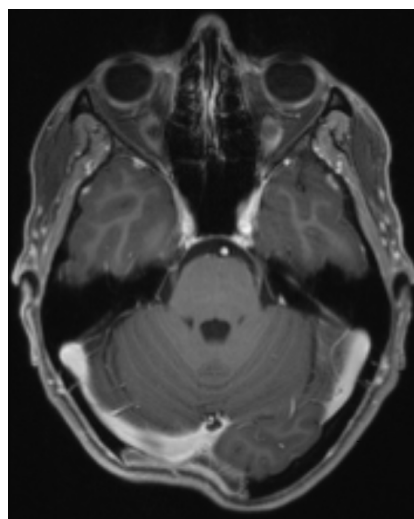
**Figure 1.** (a) Plain CT head (bone window) showing the extent of erosion with involvement of the entire thickness of the skull; (b) 3D reconstruction of skull demonstrating the intricate architecture of the tumour.



**Figure 2.** Whole body bone scan with solitary lesion in the occiput demonstrating a photopaenic centre with a peripheral rim of osteoblastic activity.

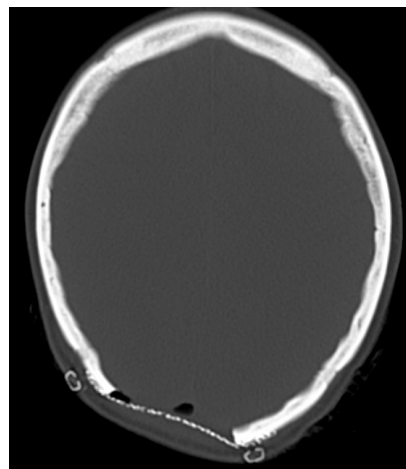


(a)

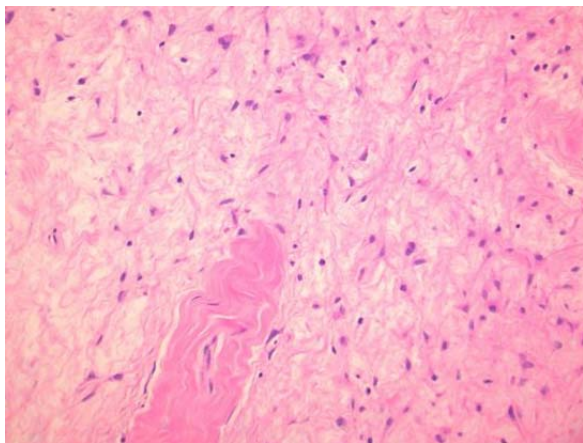


(b)

**Figure 3.** (a) Sagittal T1-weighted MRI post-contrast which reveals a lytic lesion centred on the occipital bone with enhancement; (b) Axial slice showing the close relationship of this tumour with the underlying dural venous sinuses.



**Figure 4.** Plain CT head day 1 post-operatively. Titanium mesh was fashioned and used to cover the defect in the occipital bone.



**Figure 5.** H&E stained section ( $\times 20$  magnification) of tumour which is composed of a loose fibrous type stroma in which cytologically bland stellate and spindle cell forms are seen.

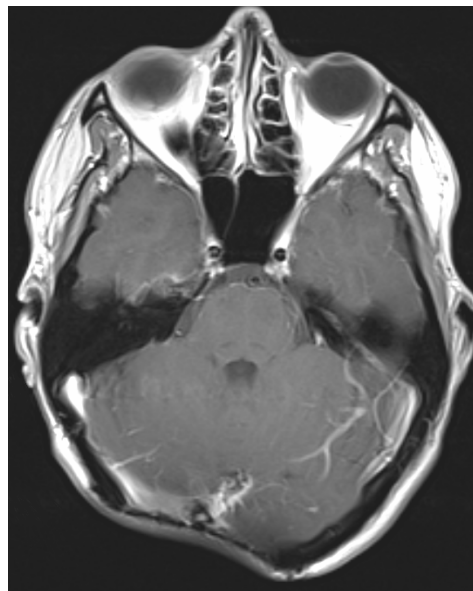
1 year post-operatively did not show any evidence of disease recurrence (**Figure 6**). The patient was asymptomatic.

### 3. Discussion

Although more commonly recognised as a soft tissue tumour, BFH is also encountered in bone and rarely in the skull. It is discussed in the WHO classification of soft tissue and bone tumours as one of two types of fibrohistiocytic tumours, the other being the malignant variant [2].

Only one other case report in the literature describes BFH involving the neurocranium. In that particular paper, Ideguchi *et al.* [1] discuss a case of a 33-year-old woman with a right occipital lesion causing raised intracranial pressure secondary to occlusion of the adjacent dural venous sinus. The tumour underwent resection with preservation of collateral veins and imaging at the 6 month follow-up confirmed eradication of the tumour. Tubbs *et al.* [3] describe a case of a BFH involving the skull base of an infant. This lesion was discovered incidentally and was diagnosed after biopsy but did not undergo any further intervention. At 18 months, the child remained asymptomatic with no gross increase in the tumour size on imaging.

Malignant fibrous histiocytoma (MFH) involving the skull is also described in a handful of case reports and its propensity to invade into the adjacent soft tissue, dura and brain parenchyma, results in a more aggressive course with a tendency for recurrence. A case presented by Joo *et al.* [4] of an intraosseous skull lesion, had similar characteristics and radiological features as the case described here, however despite lack of aggressive features macroscopically, the lesion recurred within 3 months.



**Figure 6.** Follow-up MRI scan (T1-weighted, post-contrast) at 1 year post surgery. No evidence of disease recurrence demonstrated.

In our case, given the lack of malignant features on the frozen section, the decision was to conduct a limited resection without margin.

### 4. Conclusion

Overall, this case highlights a rare tumour of the skull, which should nevertheless form part of the differential diagnosis when such lesions are encountered. Given limited reports of this particular entity in the literature, the natural history of BFH is not clearly defined. Interestingly, in a review by Bielamowicz *et al.* [5] of 18 cases of BFH involving the head and neck, a recurrence rate of 11% was reported. However, BFH of bone appears to follow a more indolent course than its malignant counterpart and thus aggressive or radical tumour resection may not be necessary unless symptomatic or causing significant mass effect.

### 5. Acknowledgements

The authors thank Dr. Sophia Otto (Pathologist, RAH) for indicating the histological diagnosis and providing the image of the slide used in this article.

### REFERENCES

- [1] M. Ideguchi, K. Kajiwara, K. Yoshikawa, S. Kato, M. Fujii, H. Fujisawa and M. Suzuki, "Benign Fibrous Histiocytoma of the Skull with Increased Intracranial Pressure Caused by Cerebral Venous Sinus Occlusion," *Journal of Neurosurgery*, Vol. 111, No. 3, 2009, pp. 504-518. <http://dx.doi.org/10.3171/2008.11.JNS081206>

- [2] C. D. M. Fletcher, J. A. Bridge, P. Hogendoorn and F. Mertens, "WHO Classification of Tumours of Soft Tissue and Bone," 4th Edition, Vol. 5, WHO Press, Geneva, 2013.
- [3] R. S. Tubbs, D. R. Kelly, J. L. Pugh, M. Loukas and W. J. Oakes, "Benign Fibrous Histiocytoma of the Skull Base," *Journal of Neurosurgery*, Vol. 106, 2007, pp. 65-67.
- [4] M. Joo, G. J. Lee, Y.-C. Koh, O.-K. Kwon and Y.-K. Park, "Primary Intraosseous Malignant Fibrous Histiocytoma of the Skull: A Case Report," *Journal of Korean Medical Science*, Vol. 18, 2003, pp. 609-613.
- [5] S. Bieclamowicz, M. S. Dauer, B. Chang and M. C. Zimmerman, "Non-Cutaneous Benign Fibrous Histiocytoma of the Head and Neck," *Otolaryngology Head and Neck Surgery*, Vol. 113, No. 1 1995, pp. 140-146.  
[http://dx.doi.org/10.1016/S0194-5998\(95\)70159-1](http://dx.doi.org/10.1016/S0194-5998(95)70159-1)